

Contents lists available at [ScienceDirect](http://www.sciencedirect.com)

African Journal of Emergency Medicine

journal homepage: www.sciencedirect.com

COMMENTARY

Cervical collars and immobilisation: A South African best practice recommendation



Minerves et immobilisations: Recommandation tirée des meilleures pratiques sud-africaines

D. Stanton^{a,*}, T. Hardcastle^b, D. Muhlbauer^c, D. van Zyl^d^a Netcare Education, Faculty of Emergency and Critical Care, South Africa^b University of Kwazulu Natal, Trauma Surgery Training Unit, Inkosi Albert Luthuli Central Hospital Trauma Service and Trauma ICU, South Africa^c Department of Emergency Medical Care and Rescue, Durban University of Technology, South Africa^d Life Flora Hospital Advanced Life Support Unit, South Africa

ARTICLE INFO

Article history:

Received 15 July 2016

Revised 22 November 2016

Accepted 10 January 2017

Available online 28 January 2017

ABSTRACT

Introduction: The consequences of spinal injury as a result of trauma can be devastating. Spinal immobilisation using hard trauma boards and rigid cervical collars has traditionally been the standard response to suspected spinal injury patients even though the risk may be extremely low. Recently, adverse events due to the method of immobilisation have challenged the need for motion restriction in all trauma patients. International guidelines have been published for protection of the spine during transport and this article brings those guidelines into the South African context.

Recommendations: Trauma patients need to be properly assessed using both an approved list of high and low risk factors, as well as a thorough examination. They should then be managed accordingly. Internationally validated assessment strategies have been developed, and should be used as part of the patient assessment. The method of motion restriction should be selected to suit the situation. The use of a vacuum mattress is the preferable technique, with the use of a trauma board being the least desirable.

Conclusion: The need for motion restriction in suspected spinal injury should be properly evaluated and appropriate action taken. Not all trauma patients require spinal motion restriction.

© 2017 African Federation for Emergency Medicine. Publishing services provided by Elsevier B.V. This is an open access article under the CC BY-NC-ND license (<http://creativecommons.org/licenses/by-nc-nd/4.0/>).

ABSTRACT

Introduction: Les conséquences des lésions de la moelle épinière suite à un traumatisme peuvent être dévastatrices. L'immobilisation de la colonne vertébrale au moyen d'une planche dorsale rigide et de minerves rigides constituait par le passé la réponse standard aux patients que l'on suspectait de souffrir de lésions de la moelle épinière, même si le risque pouvait être extrêmement faible. Récemment, des événements indésirables qui se sont produits du fait de cette méthode d'immobilisation ont remis en question la nécessité de restreindre les mouvements chez tous les patients victimes de traumatisme. Des directives internationales ont été publiées sur la protection de la colonne vertébrale au cours du transport, et cet article adapte ces directives au contexte sud-africain.

Recommandations: Les patients victimes de traumatisme doivent être adéquatement évalués en utilisant une liste approuvée de facteurs de risques faibles et élevés, et en procédant à un examen approfondi. Ils devraient être pris en charge en conséquence. Des stratégies d'évaluation validées au niveau international ont été développées, et devraient être utilisées dans le cadre de l'évaluation du patient. La méthode de restriction des mouvements devrait être sélectionnée en fonction de la situation. L'utilisation d'un matelas immobilisateur à dépression constitue la technique privilégiée, l'utilisation d'une planche dorsale étant la moins recommandée.

Peer review under responsibility of African Federation for Emergency Medicine.

* Corresponding author.

E-mail address: david.stanton@netcare.co.za (D. Stanton).<http://dx.doi.org/10.1016/j.afjem.2017.01.007>

2211-419X/© 2017 African Federation for Emergency Medicine. Publishing services provided by Elsevier B.V.

This is an open access article under the CC BY-NC-ND license (<http://creativecommons.org/licenses/by-nc-nd/4.0/>).

Conclusion: La nécessité de restreindre les mouvements en cas de suspicion de lésions de la moelle épinière devrait être adéquatement évaluée et des mesures appropriées doivent être prises. Il n'est pas nécessaire de restreindre les mouvements de la colonne vertébrale chez tous les patients de traumatisme. © 2017 African Federation for Emergency Medicine. Publishing services provided by Elsevier B.V. This is an open access article under the CC BY-NC-ND license (<http://creativecommons.org/licenses/by-nc-nd/4.0/>).

African relevance

- Injuries – including spinal injuries – are a significant contributor to morbidity, both nationally and on the continent.
- Despite resource restrictions, treatment of spinal-injured patients needs to be applied correctly to optimise outcomes.
- Unnecessary spinal immobilisation is unproven and wastes valuable resources that can be better applied elsewhere in the care system.

Introduction

In April 2016, we performed a structured review of the literature in English-language publications in the Pubmed and Cochrane libraries, using the following search terms: 'spinal injuries' OR 'spinal cord injuries' AND 'emergency treatment' OR 'emergency care' OR 'first aid' AND 'immobilisation' OR 'immobilization' OR 'trauma board' OR 'spine board' OR 'cervical collar'.

The search revealed no randomised controlled trials. Some guideline documents were identified, and these were used as the influences of this guideline. The main guideline documents identified were:

- 1) ACEP Board of Directors: EMS management of patients with potential spinal injury [1].
- 2) Faculty of Pre-hospital Care (UK): Pre-hospital spinal immobilisation: An initial consensus statement [2].
- 3) International Trauma Life Support: Long backboard use for spinal motion restriction of the trauma patient [3].
- 4) Faculty of Pre-hospital Care (UK): Minimal patient handling: A faculty of pre-hospital care consensus statement [4].
- 5) EMS spinal precautions and the use of the long backboard – Resource document to the position statement of the national association of EMS Physicians and the American College of Surgeons Committee on Trauma [5].

Spinal injury due to trauma is devastating even though the occurrence of actual cervical injury in trauma cases is rare (2–4%). Of those with a skeletal cervical injury only 20% will have cord injury [6–9]. The force required to fracture the spine is high, with one study showing that 1000 N is required to fracture the cervical spine [10] and another showing a minimum of 3000 N to fracture the lumbar spine [11], making such injuries unlikely. There has, however, been significant concern that a minor injury can become debilitating during the process of moving the patient.

In order to prevent secondary injury, spinal immobilisation using rigid cervical collars and hard trauma boards has been advocated as the mainstay of care in trauma patients for the past few decades [12]. In certain situations it has become standard practice to immobilise every trauma patient [13,14], usually for “just-in-case” purposes.

Evidence of early secondary deterioration from spinal injuries is very rare and records of sudden deterioration following sudden movement are not very readily available [15,16].

There has been much literature published in recent years that challenges the tradition of spinal immobilisation, with descriptions of real adverse events caused by the immobilisation techniques [9,13]. While management of potential spinal injury is important

[17], the interventions taken should not cause adverse events and further deterioration in the patient's condition.

The term “spinal immobilisation” is also misleading, as total non-movement is near impossible to achieve. To this end the term “motion restriction” is more commonly used, as it is more descriptive of the desired objective.

International guidelines have been published to balance the need for spinal stability and reduction of adverse events [1,2,4]. This article sets out to update the practice of spinal motion restriction and present South African guidelines which are in line with current research and clinical understanding.

Recommendations

Recognition of spinal injury

The identification of the injured spinal cord is often very difficult in the prehospital setting, and thus appropriate action should be taken to manage patients that may have such an injury. A thorough assessment, using internationally validated tools, will safely allow for sound treatment actions.

Accepted neurological and orthopaedic signs and symptoms indicating a high risk of spinal cord injury include [1]:

- Pain over the spine on palpation or movement.
- Obvious deformity of the spinal column.
- Unexplained hypotension coupled with absence of a tachycardia.
- Decreased motor and sensory function in upper or lower extremities; including pins-and-needles or loss of sensation (numbness).
- Weakness or loss of movement (paralysis).

Patient assessment

The Canadian C-Spine rule is a validated and reliable tool to assess the neck for the presence of a possible cervical spinal fracture [6,7,18]. To be reliable the patient must be able to communicate, not be under the influence of drugs or alcohol and be willing to cooperate [19]. It must be borne in mind that this tool evaluates the neck only, and motion restriction of the rest of the spine may be required, dependent on mechanism and evaluation.

The C-Spine rule uses factors derived from the mechanism of injury [7,20] to determine need for motion restriction (Fig. 1). If high risk factors are present, motion restriction should be performed, while if there are only low risk factors present the attendant can consider clearing the cervical spine.

Spinal motion restriction is generally not indicated for penetrating trauma [2,21–23]. If there are signs of focal neurological fallout (such as pins-and-needles, paraesthesia, weakness), then spinal motion restriction may be considered, but this should not delay the transportation of the patient.

Patient management

Four central areas are important in the management of a patient with a potential spinal injury: minimal patient handling, extrication procedures, cervical spinal management including collars, and spinal motion restriction.

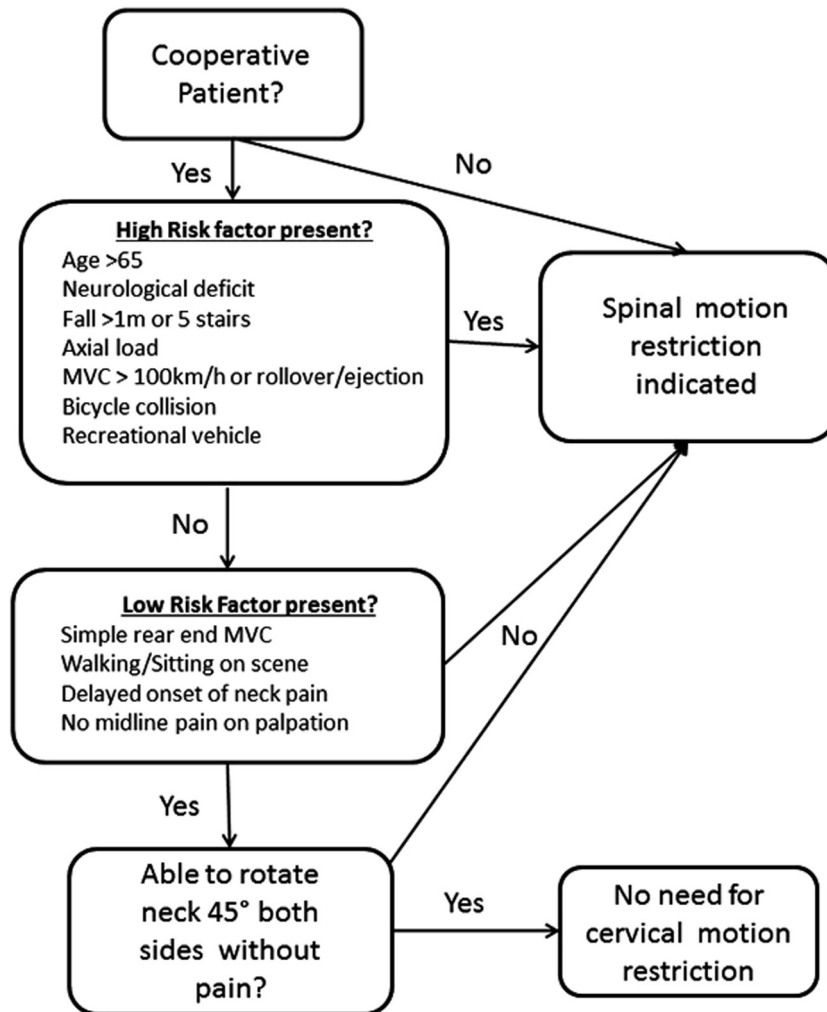


Fig. 1. High and low risk factors decision process for cervical spine motion restriction as taken from the Canadian C-Spine rule [7].

Minimal patient handling

The concept of minimal patient handling means that the patient should be moved the least number of times possible. Every movement should be deliberate and with a purpose. Where possible, the log roll is not recommended in the prehospital setting [24]. Techniques such as the unit lift, sliding using a trauma board, or a scoop stretcher to lift the patient are recommended [4].

Extrication concepts

Extrication of patients out of a vehicle is a common event faced by Emergency Medical Service (EMS) providers in South Africa. This has turned into a rather complex event, and the following concepts should be considered:

- It is recommended that conscious patients not under the influence of alcohol or drugs, who have no distracting injuries and who are not physically entrapped, should be encouraged to self-extricate, and climb onto a stretcher. If they experience pain then they should be told to stop and the extrication should be completed by the EMS crew using an acceptable technique [2].
- It is recommended that conscious patients who have already self-extricated may walk to the ambulance and climb onto a stretcher. They can then be assessed, and motion restricted as needed [2].

- For extrication purposes, a trauma board can be a useful tool. It is recommended that it be used for the extrication only, to slide the patient out of vehicle and then the patient should be placed on a preferable device for transport [3,4,25].
- The Kendrick Extrication Device (KED) takes a long time to apply and gives a false sense of motion restriction. Its use is not recommended [26].

Cervical spine management

A large body of evidence exists that challenges the value of cervical collars in the management of cervical spinal injuries. Adverse events such as increasing intracranial pressure [27–33], increased movement in unstable fractures [9,34], as well as tissue necrosis [35,36] and comfort factors have been described. To date, no human patient study has demonstrated clear benefit from the application of a rigid cervical collar in patients with neck injury [37].

Due to the risk of these adverse events and lack of efficacy, the use of hard cervical collars is not recommended [2,9,14,37].

Care in management of the cervical spine includes manual immobilisation, positioning the patient in a comfortable position and use of head blocks or other soft devices. The patient should also be coached to reduce neck movement where possible.

Spinal motion restriction

The technique of strapping a patient to a trauma board is not without its harmful effects. These may include respiratory compromise [38,39], pressure wounds [13,14], pain [40,41] and claustrophobia[40].

Should the decision be taken to motion restrict the patient, it is recommended that the following be considered:

- There is little value in a standing take-down. It is recommended that patients walking around on scene can walk to and lie themselves down on the ambulance stretcher [2,4].
- Selection of devices for the transport of motion restricted patients should be in the following descending order of preference:
 - 1) Vacuum mattress[2].
 - 2) Scoop stretcher[2].
 - 3) Patients can also be motion restricted on a normal ambulance stretcher [2].
 - a. Patients can be coached to remain still if they are awake.
 - b. Head blocks can be attached to the ambulance stretcher for unresponsive patients.

Transport of a patient on a trauma board is strongly not recommended. While it is a valuable tool for moving patients, there is no benefit to transporting a patient on this device [1].

Monitoring/transport

For patients transported on scoop stretchers, care must be taken to minimise the complications of pressure related problems [42]. It is recommended that such care include:

- For unconscious patients, the provision of pressure care should be a consideration [4].
- Removing the patient off of the scoop stretcher as soon as possible once arriving at the hospital [4].
- Remembering that scoop stretchers are poor insulators, and that measures to avoid hypothermia must be provided [4].

Documentation

The following events are important to document:

- 1) The process used to evaluate the spine, findings and decision for or against motion restriction.
- 2) The technique used for spinal motion restriction.
- 3) Pressure care performed.

Conclusion

While the effects of spinal injuries are severe, medical care providers should provide the appropriate care that will restrict injuries to the spinal cord while also not producing any adverse events. Treatment choices should be guided by evidence, and selected following the performance of adequate patient assessment.

The use of hard cervical collars and trauma boards are not recommended and where possible other more suitable methods for motion restriction should be used.

Conflicts of interest

Tim Hardcastle is an associate editor for the African Journal of Emergency Medicine. Dr. Hardcastle was not involved in the edit-

ing or peer review process of this paper. The authors declare no further conflicts of interest.

Authors' contributions

TH and DS recognised the need and enlisted DM and DVZ for their expertise. TH, DS, DM and DVZ constructed the framework, and DS wrote the initial draft. TH, DM and DVZ revised the manuscript. TH, DS, DM and DVZ approved the final version for submission.

Acknowledgements

The guidance on which this paper is based has been endorsed by the Trauma Society of South Africa and the International Trauma Life Support group (Southern Africa Chapter).

References

- [1] ACEP Board of Directors. EMS management of patients with potential spinal injury. *Ann Emerg Med* 2015;66:445. doi: <http://dx.doi.org/10.1016/j.annemergmed.2015.07.510> [PMID: 26398182].
- [2] Connor D, Greaves I, Porter K, Bloch M. Pre-hospital spinal immobilisation: an initial consensus statement. *Emerg Med J* 2013;30(12):1067–9 [[10.1136/emmermed-2013-203207](http://dx.doi.org/10.1136/emmermed-2013-203207), PMID: 24232011].
- [3] Alson RC, Copeland D. Long backboard use for spinal motion restriction of the trauma patient. 8 September 2015; <<https://www.itrauma.org/wp-content/uploads/2014/07/SMR-Resource-Documents-FINAL-Publication-6-28-14.pdf>>. Accessed 28 March 2016.
- [4] Moss R, Porter K, Greaves I. Minimal patient handling: a Faculty of Pre-hospital Care consensus statement. *Trauma* 2015;17(1):70–2. doi: <http://dx.doi.org/10.1136/emmermed-2013-203205> [PMID: 24232010].
- [5] White CC, Domeier RM, Millin MG. EMS spinal precautions and the use of the long backboard—resource document to the position statement of the National Association of EMS Physicians and the American College of Surgeons Committee on Trauma. *Prehosp Emerg Care* 2014;18(2):306–14 [<http://dx.doi.org/10.3109/10903127.2014.884197>, PMID: 24559236].
- [6] Stiell IG, Clement C, McKnight RD, et al. The Canadian C-spine rule versus the NEXUS low-risk criteria in patients with trauma. *N Engl J Med* 2003;349(26):2510–8. doi: <http://dx.doi.org/10.1056/NEJMoa031375> [PMID:14695411].
- [7] Stiell IG, Wells G, Vandemheen KL, et al. The Canadian C-spine rule for radiography in alert and stable trauma patients. *JAMA* 2001;286(15):1841–8. doi: <http://dx.doi.org/10.1001/jama.286.15.1841> [PMID:11597285].
- [8] Hasler RM, Exadaktylos AK, Bouamra O, et al. Epidemiology and predictors of spinal injury in adult major trauma patients: European cohort study. *Eur Spine J* 2011;20(12):2174–80. doi: <http://dx.doi.org/10.1007/s00586-011-1866-7> [PMID: 21644051].
- [9] Sundström T, Asbjørnsen K, Habiba S, et al. Prehospital use of cervical collars in trauma patients: a critical review. *J Neurotrauma* 2014;31(6):531–40. doi: <http://dx.doi.org/10.1089/neu.2013.3094> [PMID: 23962031].
- [10] Yoganandan N, Stemper BD, Pintar FA, et al. Cervical spine injury biomechanics: applications for under body blast loadings in military environments. *Clin Biomech* 2013;28(6):602–9. doi: <http://dx.doi.org/10.1016/j.clinbiomech.2013.05.007> [PMID: 23796847].
- [11] Yoganandan N, Arun MWJ, Stemper BD, et al. Biomechanics of human thoracolumbar spinal column trauma from vertical impact loading. *Ann Adv Automot Med* 2013;57:155 [DOI: none, PMID: 24406955].
- [12] American College of Surgeons' Committee on Trauma: International ATLS Working Group. *Advanced Trauma Life Support (ATLS)*. 9th ed. American College of Surgeons; 2012. p. 1363–6. [<http://dx.doi.org/10.1097/TA.0b013e31828b82f5> PMID: 23609291].
- [13] Hauswald M, Braude D. Spinal immobilization in trauma patients: is it really necessary? *Curr Opin Crit Care* 2002;8(6):566–70 [DOI: none, PMID: 12454543].
- [14] Hauswald M, Tandberg D, Omar Z. Out-of-hospital spinal immobilization: its effect on neurologic injury. *Acad Emerg Med* 1998;5(3):214–9. doi: <http://dx.doi.org/10.1111/j.1553-2712.1998.tb02615.x> [PMID: 9523928].
- [15] Oto B, Corey DJ, Oswald J, Sifford D, Walsh B. Early secondary neurologic deterioration after blunt spinal trauma: a review of the literature. *Acad Emerg Med* 2015;22. doi: <http://dx.doi.org/10.1111/ajem.12765> [PMID: 26394232].
- [16] Muckart DJ, Bhagwanjee S, van der Merwe R. Spinal cord injury as a result of endotracheal intubation in patients with undiagnosed cervical spine fractures. *Anesthesiology* 1997;87(2):418–20. doi: <http://dx.doi.org/10.1097/00000542-199708000-00029> [PMID: 9286906].
- [17] Todd N, Skinner D, Wilson-MacDonald J. Secondary neurological deterioration in traumatic spinal injury data from medicolegal cases. *Bone Joint J* 2015;97(4):527–31. doi: <http://dx.doi.org/10.1302/0301-620X.97B4.34328> [PMID:25820893].

- [18] Vaillancourt C, Stiell IG, Beaudoin T, Maloney J, et al. The out-of-hospital validation of the Canadian C-Spine Rule by paramedics. *Ann Emerg Med* 2009;54(5):663–71. doi: <http://dx.doi.org/10.1016/j.annemergmed.2009.03.008> [PMID: 19394111].
- [19] Anderson PA, Gugala Z, Lindsey RW, Schoenfeld AJ, Harris MB. Clearing the cervical spine in the blunt trauma patient. *J Am Acad Orthop Surg* 2010;18(3):149–59. doi: <http://dx.doi.org/10.5435/00124635-201003000-00004> [PMID: 20190105].
- [20] Domeier RM, Frederiksen SM, Welch K. Prospective performance assessment of an out-of-hospital protocol for selective spine immobilization using clinical spine clearance criteria. *Ann Emerg Med* 2005;46(2):123–31. doi: <http://dx.doi.org/10.1016/j.annemergmed.2005.02.004> [PMID: 16046941].
- [21] Haut ER, Kalish BT, Efron DT, et al. Spine immobilization in penetrating trauma: more harm than good? *J Trauma Acute Care Surg* 2010;68(1):115–21. doi: <http://dx.doi.org/10.1097/TA.0b013e3181c9ee58> [PMID: 20065766].
- [22] Barkana Y, Stein M, Scope A, et al. Prehospital stabilization of the cervical spine for penetrating injuries of the neck-is it necessary? *Injury* 2000;31(5):305–9. doi: [http://dx.doi.org/10.1016/S0020-1383\(99\)00298-3](http://dx.doi.org/10.1016/S0020-1383(99)00298-3) [PMID: 10775682].
- [23] Vanderlan WB, Tew BE, McSwain NE. Increased risk of death with cervical spine immobilisation in penetrating cervical trauma. *Injury* 2009;40(8):880–3. doi: <http://dx.doi.org/10.1016/j.injury.2009.01.011> [PMID: 19524236].
- [24] Conrad BP, Del Rossi G, Horodyski MB, et al. Eliminating log rolling as a spine trauma order. *Surg Neurol Int* 2012;3(Suppl. 3):S188. doi: <http://dx.doi.org/10.4103/2152-7806.98584> [PMID: 22905325].
- [25] Wampler DA, Pineda C, Polk J, et al. The long spine board does not reduce lateral motion during transport – a randomized healthy volunteer crossover trial. *Am J Emerg Med* 2016;34(4):717–21. doi: <http://dx.doi.org/10.1016/j.ajem.2015.12.078> [PMID: 26827233].
- [26] Brown N. Should the Kendrick Extrication Device have a place in pre-hospital care? *J Paramedic Pract* 2015;7(6):300–4 [DOI: none, PMID: none].
- [27] Raphael J, Chotai R. Effects of the cervical collar on cerebrospinal fluid pressure. *Anaesthesia* 1994;49(5):437–9. doi: <http://dx.doi.org/10.1111/j.1365-2044.1994.tb03482.x> [PMID: 8209990].
- [28] Davies G, Deakin C, Wilson A. The effect of a rigid collar on intracranial pressure. *Injury* 1996;27(9):647–9. doi: [http://dx.doi.org/10.1016/S0020-1383\(96\)00115-5](http://dx.doi.org/10.1016/S0020-1383(96)00115-5) [PMID: 9039362].
- [29] Kolb JC, Summers RL, Galli RL. Cervical collar-induced changes in intracranial pressure. *Am J Emerg Med* 1999;17(2):135–7. doi: [http://dx.doi.org/10.1016/S0735-6757\(99\)90044-X](http://dx.doi.org/10.1016/S0735-6757(99)90044-X) [PMID: 10102310].
- [30] Ahmad M, Butler J. Cervical collars and intracranial pressure. *Emerg Med J* 2001;18(5):380. doi: [http://dx.doi.org/10.1016/S0735-6757\(99\)90044-X](http://dx.doi.org/10.1016/S0735-6757(99)90044-X) [PMID: 11559616].
- [31] Mobbs RJ, Stoodley MA, Fuller J. Effect of cervical hard collar on intracranial pressure after head injury. *ANZ J Surg* 2002;72(6):389–91. doi: <http://dx.doi.org/10.1046/j.1445-2197.2002.02462.x> [PMID: 12121154].
- [32] Stone MB, Tubridy CM, Curran R. The effect of rigid cervical collars on internal jugular vein dimensions. *Acad Emerg Med* 2010;17(1):100–2. doi: <http://dx.doi.org/10.1111/j.1553-2712.2009.00624.x> [PMID: 20015105].
- [33] Dunham CM, Brocker B, Collier BD, Gemmel DJ. Risks associated with magnetic resonance imaging and cervical collar in comatose, blunt trauma patients with negative comprehensive cervical spine computed tomography and no apparent spinal deficit. *Crit Care* 2008;12(4):R89. doi: <http://dx.doi.org/10.1186/cc6957> [PMID: 18625041].
- [34] Lador R, Ben-Galim P, Hipp JA. Motion within the unstable cervical spine during patient maneuvering: the neck pivot-shift phenomenon. *J Trauma Acute Care Surg* 2011;70(1):247–51. doi: <http://dx.doi.org/10.1097/TA.0b013e3181fd0ebf> [PMID: 21217496].
- [35] Karason S, Reynisson K, Sigvaldason K, Sigurdsson GH. Evaluation of clinical efficacy and safety of cervical trauma collars: differences in immobilization, effect on jugular venous pressure and patient comfort. *Scand J Trauma Resusc Emerg Med* 2014;22(1):37. doi: <http://dx.doi.org/10.1186/1757-7241-22-37> [PMID: 24906207].
- [36] Sparke A, Voss S, Bengler J. The measurement of tissue interface pressures and changes in jugular venous parameters associated with cervical immobilisation devices: a Systematic Review. *Scand J Trauma Resusc Emerg Med* 2013;21:81. doi: <http://dx.doi.org/10.1186/1757-7241-21-81> [PMID: 24299024].
- [37] Singletary EM, Zideman DA, De Buck ED, et al. Part 9: first aid: 2015 international consensus on first aid science with treatment recommendations. *Circulation* 2015;132(16 Suppl. 1):269–311. doi: <http://dx.doi.org/10.1161/cir.0000000000000278> [PMID: 26472857].
- [38] Totten VY, Sugarman DB. Respiratory effects of spinal immobilization. *Prehosp Emerg Care* 1999;3(4):347–52 [DOI: none, PMID: 10534038].
- [39] Cerar LK, Scirica CV, Gantar IS, et al. A comparison of respiratory patterns in healthy term infants placed in car safety seats and beds. *Pediatrics* 2009;124(3):e396–402. doi: <http://dx.doi.org/10.1542/peds.2009-0160> [PMID: 19706572].
- [40] McHugh TP, Taylor JP. Unnecessary out-of-hospital use of full spinal immobilization. *Acad Emerg Med* 1998;5(3):278–80. doi: <http://dx.doi.org/10.1111/j.1553-2712.1998.tb02632.x> [PMID: 9523943].
- [41] Bruijns SR, Guly HR, Wallis LA. Effect of spinal immobilization on heart rate, blood pressure and respiratory rate. *Prehosp Disaster Med* 2013;28(3):210–4. doi: <http://dx.doi.org/10.1017/S1049023X13000034> [PMID: 23522699].
- [42] Abram S, Bulstrode C. Routine spinal immobilization in trauma patients: What are the advantages and disadvantages? *Surgeon* 2010;8(4):218–22. doi: <http://dx.doi.org/10.1016/j.surge.2010.01.002> [PMID: 20569942].